

Volume 2, Issue 2

Research Article

Date of Submission: 26 Feb, 2026

Date of Acceptance: 27 Mar, 2026

Date of Publication: 06 Apr, 2026

Chronic Prostatitis/ Chronic Pelvic Pain Syndrome and Incomplete Response to Antibiotics: Why to Consider Fungal Infectious Like Candida A. In Some Subpopulations

Luisetto M^{1*}, Khan Farhan Ahmad², Mashori G R³, Cabianca L⁴ and Latyshev O.YU⁵

¹IMA academy international, applied pharmacologist italy

²Department of Pharmacology, JNMC Aligarh Muslim University, India

³Department of Medical & Health Sciences for Women, Peoples University of Medical and Health Sciences for Women, Pakistan

⁴Medical laboratory Turin, Citta della salute -Italy

⁵IMA academy international president

***Corresponding Author:** Luisetto M, IMA academy international, applied pharmacologist Italy.

Citation: Luisetto M., Ahmad, K. F., Mashori, G. R., Cabianca, L., Yu, L. O. (2026). Chronic Prostatitis/ Chronic Pelvic Pain Syndrome and Incomplete Response to Antibiotics: Why to Consider Fungal Infectious Like Candida A. In Some Subpopulations. *Public Health Epidemiol OA*, 2(2), 01-09.

Abstract

Aim of this work is to submit a specific case report of chronic prostatitis with incomplete response to antibiotics and the role played by Candida A.

In literature it is reported that it is needed to consider this pathogen in specific subpopulation.

The early consideration of this eventuality make possible to avoid dangerous delay in the right etiologic treatment.

In this work It is used an clinical pharmacy and pharmaceutical care approach.

Keywords: Bacterial Chronic Prostatitis, Fungal, Candida, Seminal Vesicles Volume, Relapses, Antibacterial Failure, Cultural Test, Retrograde Prostatic Echography, Diabetes, Phimosis, Clinical Pharmacy, Pharmaceutical Care, Costs Avoided

Introduction

Related the classification of the prostatitis the chronic form can be divided in infective or not infective or abacterial.

In this work are considered the cases of chronic prostatitis not abacterial in classic way, when the antibiotic therapy is not efficacy, with many relapses in presence of one or more risk factor like diabetes, wide use of antibiotics, or retrograde urologic infections or other.

According article <https://knowthecause.com/candida-and-prostatitis/>

Luke Curtis, 2020

Prostatitis Common and Debilitating

"Prostatitis can be caused by chronic bacterial or fungal infections. Fungal prostatitis ie especially common in the elderly, hospitalized, catheterized, and immunosuppressed patients. Fungal prostatitis is commonly caused by the

Candida species, especially Candida albicans and glabrata.”

And in Sch J App Med Sci
Fungal Prostatitis- Rare Masquerading Infection

Dr. Nisha Raval, Dr. Payal Kalyani

“In The Last Decades, Fungal Urinary Tract Infections Due To Candida Yeasts Have Increased Significantly. The incidence of UTI associated with Candida albicans is recently reported to be 6.8% of all microbial UTIs”

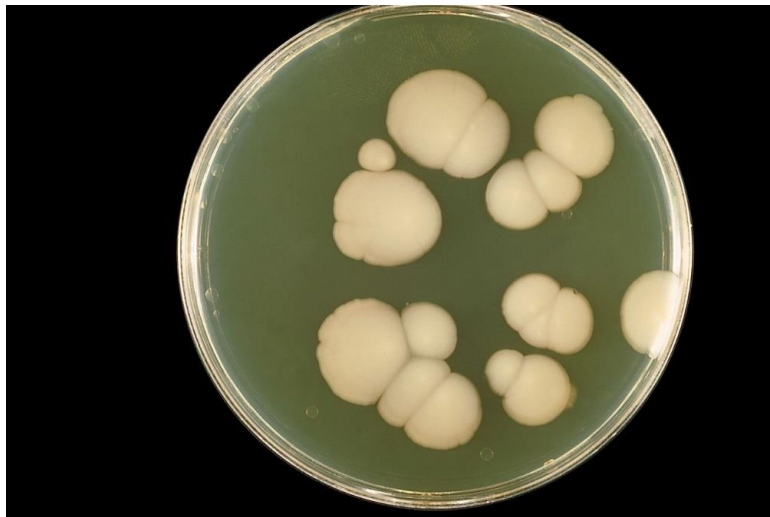

Figure 1: Candida A Culture

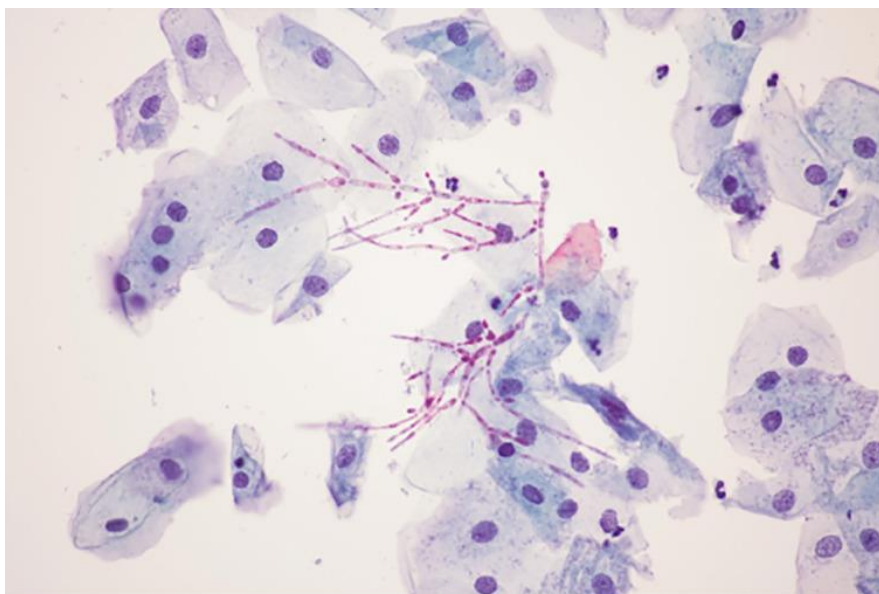


Figure 2: From doi: 10.4239/wjd.v13.i10.809 Filamentous Growth of Candida Albicans in a Vaginal Specimen, with Visible Pseudohyphae and Hyphae (magnification × 400)

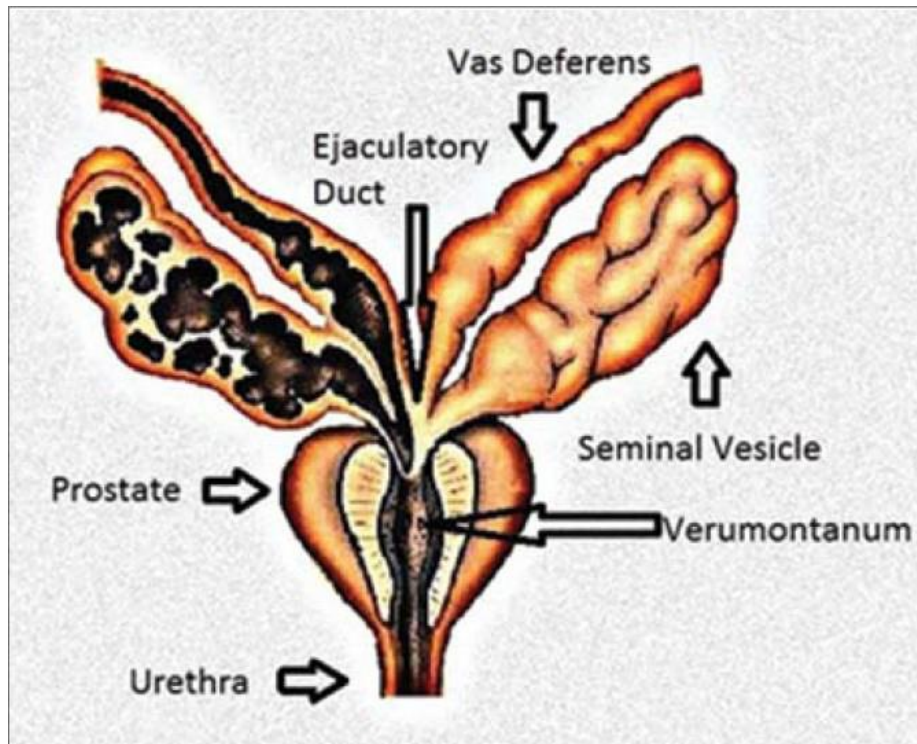


Figure 3: From doi:10.4103/2156-7514.143734 Lesions of the Seminal Vesicles and their MRI Characteristics

Mahati N Reddy, Sadhna Verma

(MAGI) Male accessory gland infection includes infections (bacterial, viral, fungal etc.) involving one or more of the following male genital organs or tracts: epididymis (epididymitis), vas deferens, seminal vesicles (seminal vesiculitis), prostate gland (prostatitis), Cowper's glands, urethra (urethritis)

John F. Fisher in 2011 Written

"Candida species enter the upper urinary tract from the bloodstream (antegrade infection) or ascend the urinary tract UT from a focus of candidal colonization at or near the urethra (retrograde infection)."

Morris B et al

"Mycotic infections are common cause of balanitis. Candida species are the most prevalent, being found in approximately 1/3 of cases. While carriage of yeasts on the penis is common, symptomatic infection is seen more often in the uncircumcised males"

Material and Methods

With an observational point of view various literature is reported and a case report form the practical part After the analys of this material a global conclusion is submitted to the researcher.

All literature come from biomedic scientific datatbase.

The figure reported (1-8) and the table help in the general meaning

Results

From literature

According article 2023 Candida prostatitis: A rare entity

Shabnam Singh et al

"Prostatitis may be acute and chronic bacterial infections (NIH Category I/II) or as asymptomatic inflammatory prostatitis (NIH Category IV). Patients with a chronic prostatitis/chronic pelvic pain syndrome, (CP/CPPS, NIH Category III) may present with a wide range of symptoms resulting from varied etiology seldom caused by fungal infections.

Occasional case reports have been published on prostatitis due to Candida sp. We report a case of an elderly diabetic patient who underwent perurethral prostatic resection for benign prostatic hyperplasia and returned with complaints of LUTS and perineal discomfort 1 month later. After repeat surgery, the TURP chips on histopathology showed features of prostate hyperplasia and prostatitis with numerous hyphae and yeast forms of Candida admixed with acute and chronic inflammatory exudate. After the confirmation by special stains and positive urine culture, a final diagnosis of prostatic candidiasis was made [1].

Aykut Demirci et al

Our patient was 51 years old and had lower urinary tract symptoms for 20 years. Cytology revealed uniform bladder epithelial cells. Spore-bearing structures on the ground were seen in smear slides. They were considered as *Candida glabrata* CG.

The patient began fluconazole 400 mg/day and doxazosin 4 mg/day. At the end of the 1 month, white particles in urine were significantly decreased, the patient's IPSS score 12; the pain score 6, urinary symptom score 2 and life quality index 3 according to NIH-CPSI, and the symptoms were regressed in an obvious manner. In urine analysis, 48 erythrocytes and 9 leukocytes were detected. Urine culture was negative. In uroflowmetry, Qmax 16 ml/s, volume 370 cc, and average flow rate 12 ml/s, and the doxazosin was stopped. At the end of the 2 month, white particles in urine disappeared completely. Fluconazole 400 mg/day was administered for a total of 8 weeks and then was discontinued. The patient was followed up for 6 months and no recurrence was then observed.

Our case has shown that fungal agents should be considered especially in patients who do not respond to medical treatment [2].

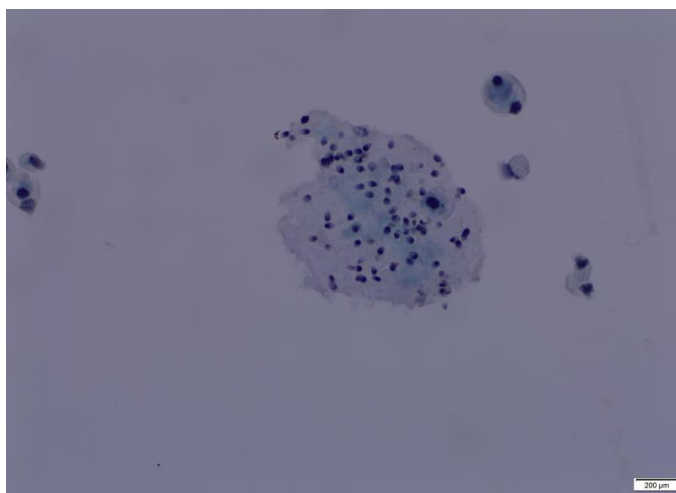


Figure 4: From A Demirci et al Microscopic Findings of Urine Cytology

Emilio Mayayo et al

"Within the infectious prostatic processes, fungi can also be a specific cause of prostatitis. Fungal prostatitis FP often appears in patients with impaired immunity and can also be rarely found in healthy patients. It can result from a disseminated infection, but it can also be localized. Fungal prostatitis FP is a nonspecific and harmless process. Diagnosis is commonly made by fine needle aspiration cytology or by biopsy" [3].

Ahmed Fouad Kotb et al

"Antifungal regimen should be considered for the majority of young adult men, presenting with chronic prostatitis/chronic pelvic pain syndrome and incomplete response to the antibiotics" [4].

Zekaver Odabasi et al

"Candiduria is commonly seen in hospitalized patients and most of the patients are asymptomatic, but it may be due to cystitis, pyelonephritis, prostatitis, epididymo-orchitis or disseminated candidiasis. Major risk factors are diabetes mellitus DM, indwelling urinary catheters, use of broad-spectrum antibiotics, urinary obstruction UO, and admission to intensive care units. Candida urinary tract infections can be caused by hematogenous spread following candidemia, or retrograde route via the urethra" [5].

Septimus, J.D. et al Infectious Diseases in Clinical Practice 2006

"With the increased use of antibiotics such as fluoroquinolones in these situations as well as widespread use of other broad-spectrum antimicrobials, fungal infections FI in general have become more prevalent. Our case adds to this growing body of literature, suggesting that clinicians need to consider fungal infections FI in patients who fail standard therapy for prostatitis, either as a primary causative organism or as secondary agents induced by broad-spectrum antibiotic use.

After 1 month of antibiotics, his dysuria progressed to perineal discomfort and burning after urination. At that time, he was seen once again by urology. Urinalysis again showed 20-30 white blood cells and 20-30 red blood cells per high power field, and rectal examination revealed a slightly boggy prostate with mild tenderness. Urine culture, prostate secretion cultures, and ejaculate cultures all grew *Candida albicans* CA at that time. Prostate ultrasound revealed no abscess.

The patient was diagnosed at that time with Candida prostatitis CP. He was started on fluconazole 400 mg daily for 6 weeks, with total resolution of symptoms after the first week of therapy. He is currently symptom-free over a year later, and follow-up urinalysis after treatment returned to normal" [6].

Wise, G.J et al A. How to diagnose and treat fungal infections in chronic prostatitis. Curr Urol 2006 "Diagnosis can be established by urine cultures or needle biopsy of the prostate PB. Prostate surgery for carcinoma or benign enlargement may detect latent fungal infection" [7].

<https://www.candidaplan.com/candida-and-prostatitis/>

Dr. McCombs

"Any male over 40 with a history of antibiotic use and swelling of the prostate, or urinary retention UR issues, should consider fungal candida as a possible cause" [8].

Tatfeng YM et al

"The presence of spermatozoa in the urine with yeast cells (Candida albicans CA) could be an indication of seminal sac infection" [9].

Vanessa Dias in 2020 Reported

"Risk factors of candiduria (presence of Candida species in urine samples) and Candida urinary tract UT infections are well established, and include the extremes of age, female sex, diabetes mellitus, prolonged hospitalization, intensive care unit admission, immunosuppressive therapy, recent use of broad-spectrum antibiotics, previous surgery (urological and nonurological), radiation therapy, genitourinary tuberculosis, neutropenia, urinary tract UT instrumentation, transplantation, abnormalities of the urinary tract UT and catheterization, among others . Renal parenchymal infection should be treated, in the same way as candidemia, using systemic antifungal agents. For the treatment of upper urinary tract infections due to the retrograde spread of Candida species, that occurs in patients with obstructive uropathy, diabetes mellitus DM and frequently concomitant bacteriuria, fluconazole is the antifungal agent of choice" [10].

Joana Rolo et al

"Semen has the ability to sustain C. albicans growth" [11].

A. E. Calogero et al in 2017

"Male accessory gland infection/inflammation is a generic acronym that indicates a set of inflammatory diseases of the male accessory sexual glands.

From a microbiological point of view, MAGIs are classified into microbial and inflammatory forms. There are much microorganisms potentially responsible of MAGI; the most common are Enterobacteriaceae (such as E. coli and Klebsiella sp.), Neisseria G., Chlamydia T, Ureaplasma urealyticum, Mycoplasma hominis, Candida albicans, and Trichomonas vag. MAGI is a consequence of canalicular spreading of agents via the urethra, prostate gland, seminal vesicles, deferent ducts, epididymis and testes.

Dohle et al.10 reported that in patients with a history of MAGI, 10% had abnormalities found on transrectal ultrasound of the prostate, such as oedema, dilatation of the seminal vesicles and ejaculatory ducts, intraprostatic calcifications and dilatation of the periprostatic venous plexus" [12].

Table 1. Ultrasound criteria for the diagnosis of male accessory gland infection.

<i>The classification of male accessory gland infection</i>	<i>Ultrasound criteria for the diagnosis</i>
Prostatitis (>2 criteria simultaneously present among the following)	(a) asymmetry of the gland volume(b) areas of low echogenicity(c) areas of high echogenicity(d) dilatation of the peri-prostatic venous plexus(e) single or multiple internal similar cystic areas(f) area(s) of moderate increase in vascularity (focal or multiple)
Vesiculitis (>2 criteria simultaneously present among the following)	(a) increased (>14 mm) anteroposterior diameter; mono- or bilateral(b) asymmetry >2.5 mm (normal 7–14 mm) compared with the contralateral vesicle(c) reduced (<7 mm) anteroposterior diameter; mono- or bilateral(d) thickened and/or calcified glandular epithelium(e) polycyclic areas separated by hyperechoic septa in one or both vesicles(f) fundus-to-body ratio >2.5(g) fundus-to-body ratio <1(h) anteroposterior diameter unchanged after recent immediate ejaculation
Epididymitis (>2 criteria simultaneously present among the following)	(a) increase in size of the head (craniocaudal diameter >12 mm) and/or of the tail (craniocaudal diameter >6 mm) (finding single or bilateral)(b) presence of multiple microcystis in the head and/or tail (finding single or bilateral)(c) low echogenicity or high echogenicity; mono- or bilateral(d) large hydrocele; mono- or bilateral(e) enlargement of the superior part of the cephalic tract and a superior-to-inferior part ratio >1(f) unchanged anteroposterior diameter of tail after ejaculation

[Open in a new tab](#)

Prostatitis: a–d=conventional ultrasound criteria;¹¹ e, f=additional ultrasound criteria.¹³

Vesiculitis: a–e=conventional ultrasound criteria;¹¹ f–h=additional ultrasound criteria.¹³

Epididymitis: a–d=conventional ultrasound criteria;¹¹ e, f=additional ultrasound criteria.¹³

Table 1: From S. La Vignera et al

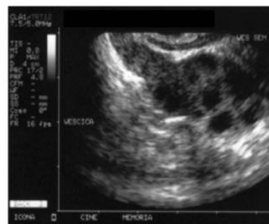


Figure 3 Ultrasound alterations more frequently detected in patients with bacterial male accessory gland infection.

Figure 5: From doi:10.1038/aja.2012.49

Types	Drugs
Antibiotics	Ciprofloxacin Levofloxacin Azithromycin Doxycycline clarithromycin
Nonsteroidal antiinflammatory	Salicylates Pirofen COX-2 inhibitors
Fibrinolytics	Serratiopeptidase Bromelain Esin
Antioxidants	Enzymatic <ul style="list-style-type: none"> • Superoxide Dismutase (SOD) • Catalase • Glutathione peroxidase Nonenzymatic <ul style="list-style-type: none"> • Glutathione • N-acetyl-cysteine (NAC) • Vitamins A, C, E • Co-Q 10 • Carnitines • Myoinositol • Lycopene
Steroidal antiinflammatory	Prednisolone
PDE-5 inhibitor	Tadalafil

Figure 6: From S. Dutta et al 2024

Mba, I.E. et al 2020

"Candida is the most implicated fungal pathogen in the clinical setting. Many factors play important roles in the pathogenesis of Candida spp. Multiple transcriptional circuits, morphological and phenotypic switching, biofilm formation, tissue damaging extracellular hydrolytic enzymes EHE, metabolic flexibility, genome plasticity, adaptation to environmental pH fluctuation, robust nutrient acquisition system, adherence and invasions (mediated by adhesins and invasins), heat shock proteins HSP , cytolytic proteins, escape from phagocytosis, evasion from host immune system HIS , synergistic coaggregation with resident microbiota, resistance to antifungal agents AA, and the ability to efficiently respond to multiple stresses are some of the major pathogenic determinants of Candida sp" [13].

N Jegadish et al

"The most common infectious etiology of balanoposthitis is candida, followed by bacterial infections caused by Streptococcus sp. and Staphylococcus aureus, viral and parasitic infections. The factors which predispose to candidal balanoposthitis include diabetes mellitus, the immunosuppression, uncircumcised penis, poor hygiene of the genitals, and tight prepuce" [14].

Meeta Singh et al, 2024

"Fungal prostatic infections are relatively uncommon; The most common causes include blastomycesdermatiditis, Coccidioidesimmitis, and Cryptococcus neoformans. Aspergillus fumigatus, Histoplasma capsulatum, and Candida albicans, and Candida glabrata are among the other rarer causes. Most fungal prostatitis occurs in urinary catheterization and use of broad-spectrum antibiotics, leading to systemic hematogenous dissemination in immunocompromised patients and elderly hosts with comorbidities" [15].

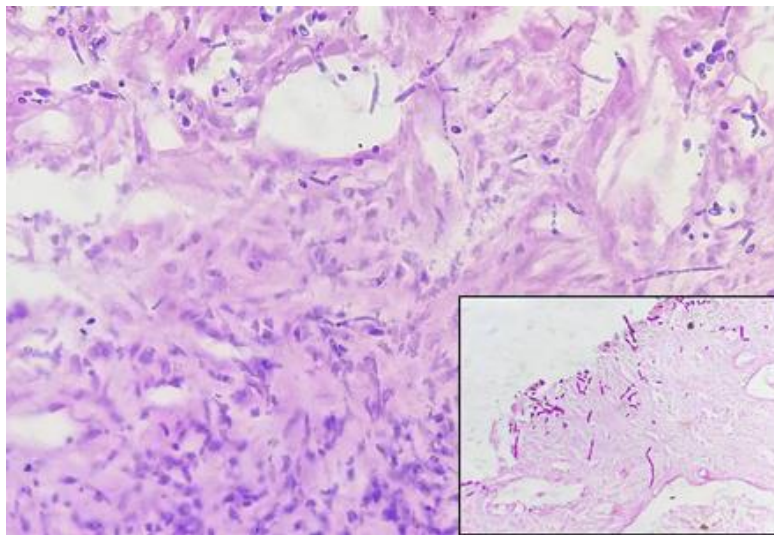


Figure 7: From Meeta Singh et al Hyphae and Budding Yeast Forms of Candida, H&E stain, 400x, Inset: PAS Stain, 400x

PRACTICAL PART : Case Report

A case of adult, 120 kg, age 60 years old, diabetes type II controlled with therapy, history of recurrent prostatitis (more than 20 year, every 3 month but also more frequent).

Normal flux if not congested, light urethral restriction confirmed by retrograd uretrography, abnormal urinary fluxumetry. Ecographic prostate: microcalcification present, and seminal vesicle volume increased.

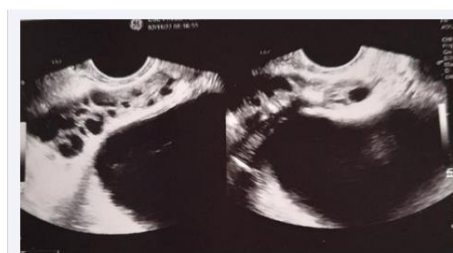

Figure 11 Transrectal Prostatic Pchography: Seminal Vesicle Important Dilatation

Figure 8: From J Urol Res 12(1): 1161

Urologic Inspection: Normal Volume

Positive seminal liquid for candida in recent time , Psa negative. Many time sitting position during the days, reduced physical activity, costipation. Great coffeine intake daily, no smoking.

Previous culture was negative.

In past positive culture for ureaplasma.

Phimosis severe present.

Worsening Contition: Aclool Intake Greatly Agravate, Spicie Use Aggravate.

Starting Episode: Expecially After A Costipation Episode Expecially or After Prolonge Sitting Position on Rigid Sitting.

Hemorrhides present, anal fissuration, history of low anal bleeding.

Ciproxin: good efficacy if prolonged 5-7-10 gg, Claritromicin good but relapses.

Sulfamidics – trimetoprim good efficacy also in preventing, Sporanox good efficacy.

Tamsulosin good to reduce bladder iperactivity, Saccaromices cerevisiaee extract supp good to stop some episode.

Fenolmicin P3 and Boisexil supp.,good efficacy if prolonged 3-5 days, Serenoa repens efficacy in reducing prostate pain and increase little the urinary flcus, Urtica dioica: efficacy.

Beclotason suppository alleviate, Saccharomyces Cerevisiae extract suppository alleviate (for competition with the Candida A.).

Quality of life worsened highly during episode. Number of episode: every mouth, but after ciproxin prolonged (7-10 days) every 6 month.

Used also Sereona repens cps and urtica dioica with efficacy in quality of life and to improve Urine flux. It was necessary to position an urinary catherer during a recent episode of urine retention dianostiched.

By emergency urology ambulatory (30 days), the flux improved for 1 year then new restiction.

Therapy with Itraconazole : Great reduction of sympthoms after 2cps, after 3cps great efficacy without using antibiotics. (1 cps at days = 100 mg) in last episode.

Discussion

in particular kind of subpopulation like diabetic patients with problems of Candida A growths also in retrograde way it is crucial to consider also fungal pathology especially if relapses with antibiotics and without neoplasm.

Obstructive uropaty, Prostatitis treated previous whit great use of antibiotics with failure ,phimosis.

Candida fungus can cause seminal vesicle inflammation (seminal vesiculitis), leading to enlargement, as semen supports its growth [12].

To be considered the hypotesis of canalicular spreading of agents via the urethra, prostate gland, seminal vesicles, [12].

Trought the transrectal ultrasound of the prostate it is possible to see oedema, dilatation of the seminal vesicles and ejaculatory ducts, intraprostatic calcifications.

Imaging (transrectal ultrasound) can show seminal vescicles enlargement.

Crucial the microbiological culture, the citology with special staining or since result of biopsy if needed by the patology [2,7].

Conclusion

it is not accetable relapses in chronic prostatitis for decade as reported in this work or in the case report submitted in the practical part: it is proposed to the researchre to modify the algoritm of diagnosis and treatemet: If many relapses after antibiotic therapy in presence of one or two factor predisposing is necessary to Exclude the fungal infections and to be evaluated the efficacy of an antimicotis [2].

The right therapy if of fungal origin make possible to reduce the antibiotics cicle (some time inefficacy) with a reduced possibility to produce new resitence.

The same antibiotics therapy can provide an environmet that can increase the micotic infections.

Also the cost for inappropriate therapy can be avoided.

Reference

1. Trop Doct . 2023 Apr;53(2):282-284. Epub 2022 Dec 26.
2. Candida prostatitis: A rare entity Shabnam Singh , Meeta Singh , Lovenish Bains , Tanu Sagar
3. Demirci, A., Bozlak, N., & Turkel, S. (2018). Chronic prostatitis developing due to candida infection: A case diagnosed 20 years later and review of up-to-date literature. *Urology Case Reports*, 20, 88-89.
4. Mayayo, E., & Fernández-Silva, F. (2014). Fungal prostatitis: an update. *Analytical and Quantitative Cytopathology and Histopathology*, 36(3), 167-176.
5. Kotb, A. F., Ismail, A. M., Sharafeldeem, M., & Elsayed, E. Y. (2013). Chronic prostatitis/chronic pelvic pain syndrome: the role of an antifungal regimen. *Central European journal of urology*, 66(2), 196.
6. Odabasi, Z., & Mert, A. (2020). Candida urinary tract infections in adults. *World journal of urology*, 38(11), 2699-2707.
7. Septimus, J. D., & Septimus, E. J. (2006). Prostatitis due to *Candida albicans*. *Infectious Diseases in Clinical Practice*, 14(4), 239.
8. Wise, G. J., & Shteynshlyuger, A. (2006). How to diagnose and treat fungal infections in chronic prostatitis. *Current urology reports*, 7(4), 320-328.
9. <https://www.candidaplan.com/candida-and-prostatitis/>
10. Tatfeng, Y. M., Agba, M. I., Nwobu, G. O., & Agbonlahor, D. E. (2003). *Candida albicans* in urinary tract or in seminal sac. *Online J Health Allied S cs*, 4, 5.
11. Dias, V. (2020). *Candida* species in the urinary tract: is it a fungal infection or not?. *Future microbiology*, 15(2), 81-83.
12. Rolo, J., Caixeirinho, P., Gomes-Ruivo, P., Gaspar, C., Fernandes, I., Palmeira-de-Oliveira, R., ... & Palmeira-de-Oliveira, A. (2020). Semen supports growth of *Candida albicans*: A putative risk factor for recurrence of vulvovaginal infections?. *Journal of Obstetrics and Gynaecology Research*, 46(9), 1893-1899.
13. Mba, I. E., & Nweze, E. I. (2020). Mechanism of *Candida* pathogenesis: revisiting the vital drivers. *European Journal of Clinical Microbiology & Infectious Diseases*, 39(10), 1797-1819.
14. Jegadish, N., Fernandes, S. D., Narasimhan, M., & Ramachandran, R. (2021). A descriptive study of the clinical and etiological profile of balanoposthitis. *Journal of Family Medicine and Primary Care*, 10(6), 2265-2271.
15. Singh, M., Singh, S., Khurana, N., Pandey, N., Bhatt, V. R., Thomas, S., ... & Kimnuntluangi, J. (2024). Histopathological evaluation of prostate lesions: A comprehensive approach.